

The added value of extended field of view in breast MRI cancer patients

Souad Elsayed Mohammed Mansour¹, Amany Mohamed Rashad Abdel-Aziz¹, Ahmed Mohamed Osman¹, Suzan Farouk Ibrahim¹

¹Department of Diagnostic & Interventional Radiology and Molecular Imaging, Ain Shams University, Cairo-Egypt.

*Corresponding author: Souad Elsayed Mohammed Mansour, Email: Souad.Elsayed@med.asu.edu.eg

Abstract. Background: Incidental extramammary findings on breast MRI may be lesions of medical importance, benign or metastatic lesions. Objective: Assessment of the added value of extending the field of view in MRI breast study for detection of extramammary findings and its impact on the diagnosis. Patients and Methods: A cross sectional study of 100 breast MRI s was conducted with extending the field of view from lower neck to upper abdominal levels. Results: 100 incidental findings were found in 69/100 (69%) examined patients. 10/100incidental findings (10%) were confirmed to be malignant while the remaining 90/100 (90%) benign. The most common site was the liver (38/69; 55.07%), followed by the bone (30/69; 43.47%), Heart (14/69; 20.28%), lung (5/69;7.24%) ,chest wall (5/69;7.24%) ,thyroid gland (3/69;4.34%) , spleen (2/69;2.89%) , left supraclavicular lymph nodes(1/69;1.44%), diaphragm(1/69;1.44%) , gall bladder (1/69;1.44%) .The incidence of incidental findings resulted to be high in that group of patients by extending the MRI field of view. MRI findings has high correct diagnosis with a high diagnostic accuracy value. Conclusion: Incidental extramammary findings on breast MRI are common. Benign lesions represent the most frequent findings, however malignant ones need to be searched especially in patients with personal history of breast cancer because they could influence the clinical patient management. Extending the field of view in breast MRI can characterize incidental findings with high accuracy value.

Keywords: Breast, MRI, incidental, Extramammry findings.

Introduction

Breast MRI (magnetic resonance imaging), also known as magnetic resonance mammography, is a non-invasive technique for breast imaging. It creates high-quality images of the breasts and has better sensitivity and specificity for the detection of breast cancer than the other currently available technologies, this is in addition to the ability for detection of other lesions beyond the mammary field which are known as extramammary findings. It is also used in the evaluation of the integrity of breast implants (1).For patients with breast cancer, MRI has increasingly been used as a method for regional staging, to more closely evaluate the breast tissue, and to obtain information on local lymph nodes, which may have implications on the management workup and may affect the treatment planning (2). Furthermore, breast MRI is effective in the evaluation of neoadjuvant therapy response (3).As the number of breast MR examinations increases, so does the number of incidental extramammary findings detected during the same examination. Some of these findings can often be clinically significant and would potentially alter patient management, requiring further investigations (4).Although many of these findings will be benign, some

will be malignant and affect disease staging. In some cases, even if only a small extramammary disease deposit is found on MRI, a woman who in an earlier era would have been treated with curative intent is now considered to have stage IV disease and generally deemed incurable. Importantly, these extramammary findings (EMFs) could delay care as work-up of non-breast findings is pursued. Previous studies have reported that 10%–18% of breast MRI studies will contain an EMF and that 9%–34% of patients who undergo a breast MRI will have an EMF (5).

Aim of the Study

Our study aimed to assess the prevalence, the location, and the imaging characteristics of the incidentally detected extramammary findings on breast MRI in the extended field of view from the lower neck to upper abdominal cuts, to determine the ability of MRI to detect the potential malignant characteristics of these findings and the impact of these findings on the patient's management.

Patients and Methods

Patients: The study was a cross sectional study of 100 patient that conducted at the Radiology Department – Ain Shams University over a course of 2 years according to the criteria of the institutional ethical and scientific committee.

Inclusion criteria: Any female patients recently diagnosed with cancer breast before any surgical intervention or any chemotherapy (CTH) or radiotherapy (RTH).

Exclusion criteria: Any contraindications to MRI as the presence of pacemakers or intra-cranial aneurysm clips. Also, any patients with history of claustrophobia or history of surgical intervention or previous CTH or RTH. Patients with triggerfish" Contact Lens, gastric reflux device, insulin pumps, and temporary trans-venous pacing leads were also excluded. Patients with contraindications to intravenous MRI contrast was excluded.

MRI breast: All MRI studies were performed by using a 1.5 Tesla superconducting Magnet (Philips Systems).

Patients' preparation: Full history was taken prior to procedure with exclusion of patients with any contra-indication to MRI study. The patients were asked to fast for 6 hours prior to the study. Serum creatinine levels were checked to ensure adequate renal function. Insertion of an intravenous cannula. Any Metallic material was removed and put outside MR room.

MRI protocol: MRI sequences were taken as follow T2 sequences, diffusion weighted imaging (DWI), T1 gradient-echo sequences which can detect markers placed after biopsy, and injected dynamic 3D sequences for performing volume and multi-planner reconstructions, which are particularly useful for locating lesions well. Including the large field image sequences (by increasing the field of view taken). Both breasts were investigated to allow mirror reading by facilitating detection of the physiological glandular contrast uptake, which limited the diagnostic value of the examination by masking a certain amount of contrast uptake, limiting aliasing artifacts and extending the field of view.

Slice thickness was less than or equal to 3 mm with pixel size less than 1 mm on each side. For multi-planar reconstruction, the voxel was optimally be isotropic and less than 1 mm.

Finally, acquisition time was less than 2 minutes as the mean enhancement time of a malignant tumor was between 90 and 120 seconds by using gadolinium injection with a dose of 0.1 mmol/kg or 0.2ml/kg and followed the rate of 1-2 ml/sec flushed by 20ml of saline. For all axial plane acquisitions, the phase encoding direction was from right to left to limit artifacts repeating cardiac and respiratory movement. For sequences in the sagittal or coronal plane, the encoding direction was anterior-posterior.

Dynamic sequences were satisfied the two major classic requirements of perfusion imaging: good temporal resolution (< 2 minutes) and good spatial resolution (1 mm)

MRI image analysis: All MRI data were transferred to and analyzed on a diagnostic workstation equipped with dedicated software for MRI examination. Images were evaluated by a senior radiology specialist and radiology consultant with 6 years and 13 years of experience in the field of breast MRI respectively in consensus searching for extra-mammary findings localized in lungs, mediastinum, chest wall, spine and upper abdominal organs. The overall prevalence and the sites of extra-mammary findings were evaluated. Breast MRI accuracy in the characterization of the incidental lesions was calculated having additional imaging (US, Bone scintigraphy, CT, and PET/CT) as reference.

Statistical analysis:

By using pass 11 program for sample size calculation , setting confidence level at 95% and margin of error at 15 % and after reviewing previous study results (Gao et al.,2017) showed that extramammary findings in incidental breast MRI were found in almost (50 %) of patients undergoing breast MR imaging ; based on that a sample size of at least 50 female patient with recent diagnosis of breast cancer before surgical intervention and undergoing breast MR imaging will be sufficient to achieve study objective.

Results:

100 patients were included in the study with age ranging from 23 years to 75 years with mean age of 49.34with mean \pm SD of 49.34 \pm 12.18. 100 patients (100%) had diagnosed with breast cancer. They were diagnosed by sono-mammography (BI-RADS5) or histo-pathological examination (BI-RADS6).

Table 1. BI-RADS5 (sono-mammography) and BI-RADS6 (histopathology examination).

BI-RADS5	63	63%
BI-RADS 6	37	37%

100 incidental findings were found in 69/100 (69%) examined patients. 10/100 incidental findings (10%) were confirmed to be malignant (Table 3) while the remaining 90/100 (90%) benign (Table 2). The most common site with incidental findings was the liver (38/69; 55.07%) i.e. fig. 1, followed by the bone (30/69; 43.47%) i.e. fig. 2, Heart (14/69; 20.28%), lung (5/69; 7.24%) i.e. fig. 3&4, chest wall

i.e. fig. 5 (5/69; 7.24%), thyroid gland (3/69; 4.34%), spleen (2/69; 2.89%), left supraclavicular lymph nodes (1/69; 1.44%) i.e. fig. 5, diaphragm (1/69; 1.44%), gall bladder (1/69; 1.44%) i.e. fig. 6. The incidence of incidental findings resulted to be high in that group of patients by extending the MRI field of view.

	No.	Percentage
Spondylodegenerative changes	29	29%
Cardiomegaly	14	14%
Hepatomegaly	11	11%
Fatty liver	10	10%
Fatty hepatomegaly	10	10%
Pulmonary atelectatic bands	3	3%
Hepatic cysts	2	2%
Accessory splenule	2	2%
Thyroid enlargement	1	1%
Thyroid cyst	1	1%
Chest wall subcutaneous lipoma	1	1%
Vertebral body hemangioma	1	1%
Hepatic hemangioma	1	1%
Pulmonary nodules	1	1%
Pleural effusion	1	1%
Calcular gall bladder	1	1%
Diaphragmatic muscle paralysis	1	1%

Table 2. MRI benign EMF findings for the studied group.

	No.	Percentage
Malignant hepatic focal lesions	4	4%
Chest wall invasion	3	3%
Left supraclavicular lymph nodes	1	1%
Chest wall edematous changes	1	1%
Malignant thyroid gland focal lesion	1	1%

Table 3. MRI malignant EMF findings for the studied group.

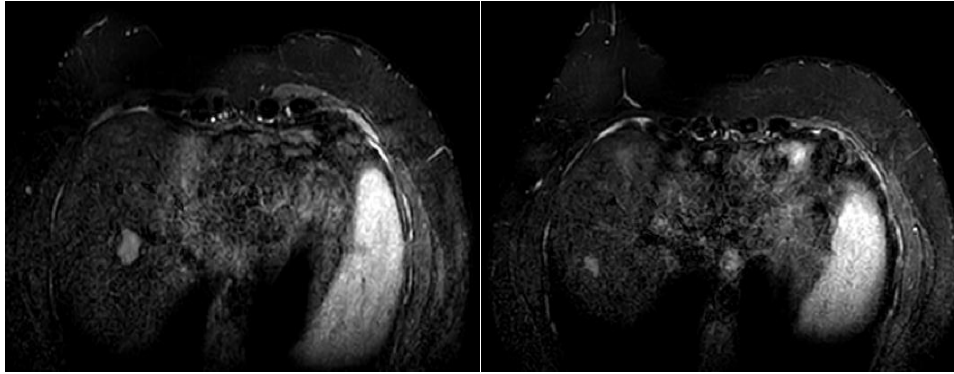


Figure 1. MRI breast study of 37 years old female patient with pathologically proven left breast infiltrative ductal carcinoma with metastatic left axillary lymph nodes. (BI-RADS-6) with axial sequences showed two hepatic focal lesions at the interface between subsegment VII and VIII measuring 1.4 cm and 2 cm.

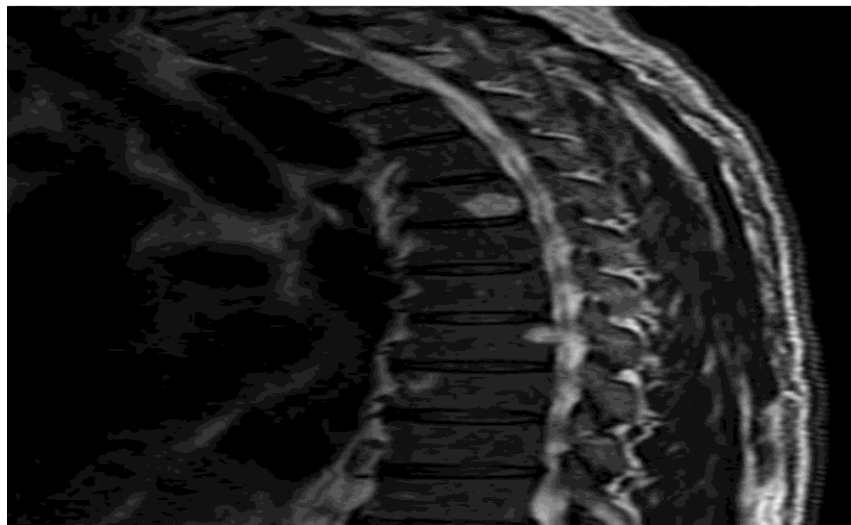


Figure 2. MRI breast study of 57 years old female patient with pathologically proven left breast axillary tail suspicious looking lesion. (BIRADS-6) with sagittal T2WI showed Vertebra body hemangioma.

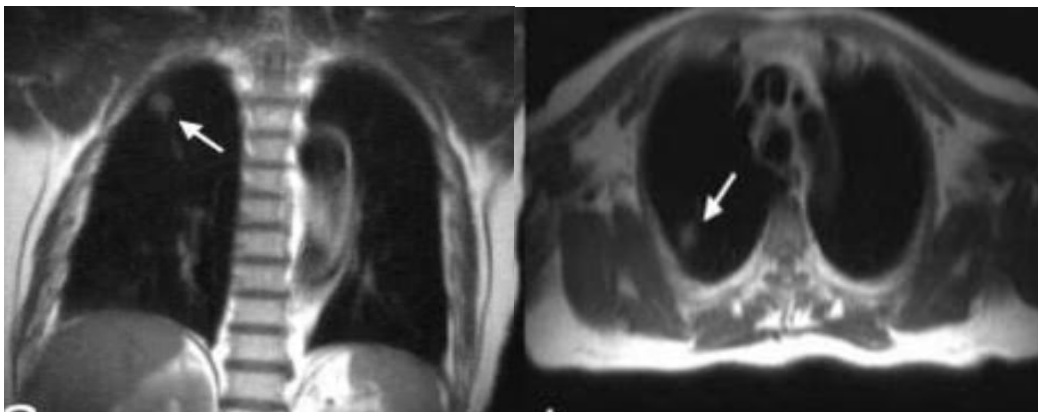


Figure 3. MRI breast study of 44 years old female patient with left breast two suspicious looking masses with left suspicious axillary lymph nodes. (BI-RADS-5) with axial and coronal sequences showed right upper lobar apical nonspecific pulmonary nodule.

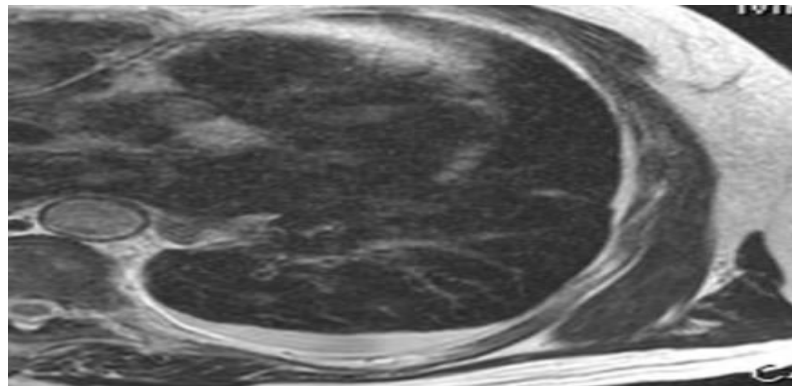


Figure 4. MRI breast study of 37 years old female patient with pathologically proven left breast invasive ductal carcinoma with pathologically enlarged left axillary lymph nodes. (BI-RADS-6) with axial T2WI showed left mild pleural effusion.

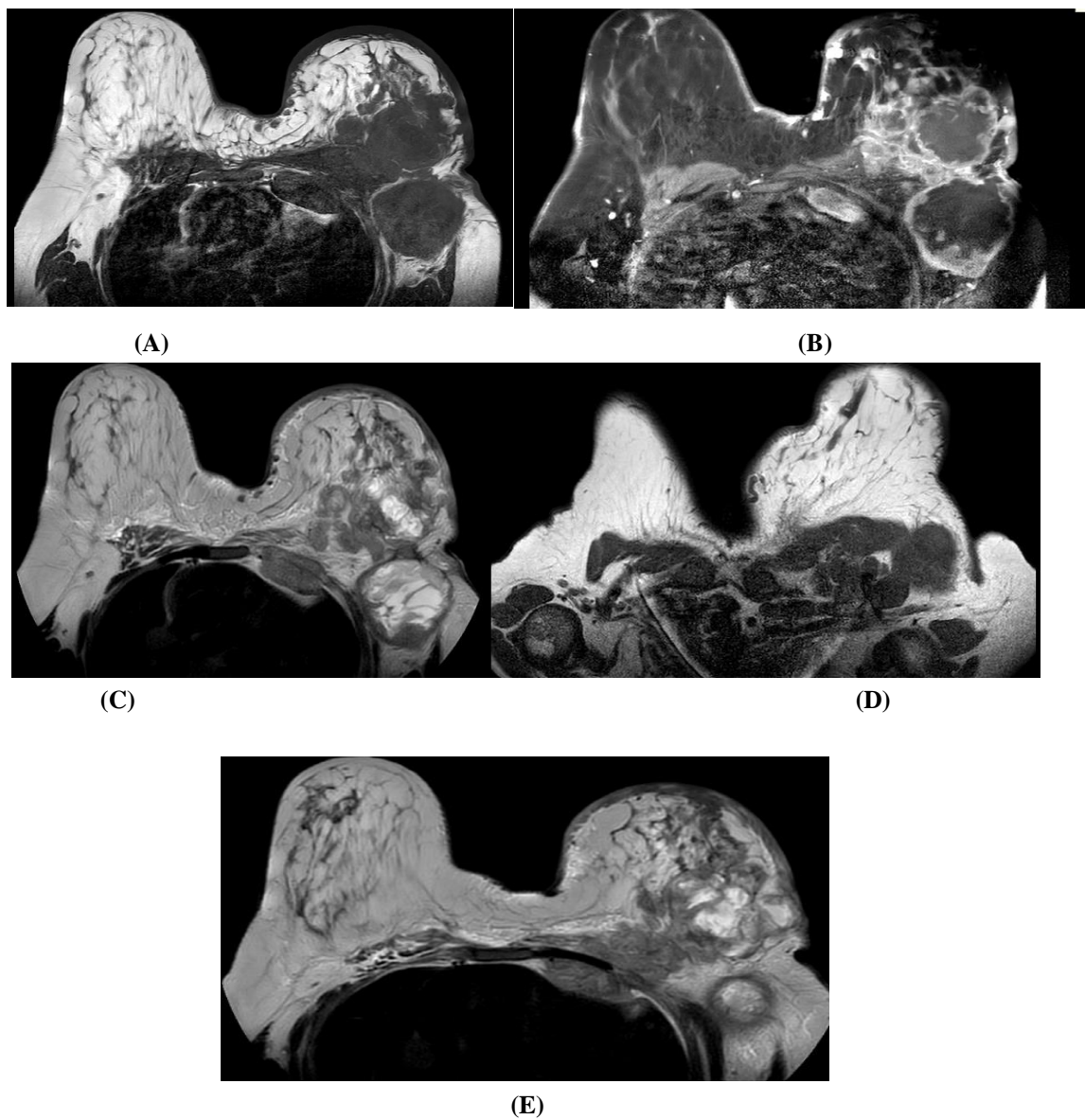


Figure 5. MRI breast study of 41 years old female patient with left sided innumerable neoplastic looking left breast and axillary soft tissue lesions with pathological axillary & subpectoral and supracalvicular lymph nodes. (BI-RADS-5) ; (A) & (B) & (C) Axial T1WI pre and post contrast and Axial T2WI showed :

- Moderate to marked skin thickening of the left breast with diffuse left breast parenchymal edema.
- Left breast is showing multiple innumerable variable sized nodular lesions with confluent appearance at its UOQ forming sizable lesion measuring $\pm 7.5 \times 7 \times 6.5$ cm showing internal multiple septations and cystic changes with irregular peripheral nodular soft tissue enhancement.
- The rest of smaller nodules are showing solid post contrast enhancement.
- These nodules are seen non-separable from left pectoral muscles which are showing corresponding edema.
- Multiple pathologically enlarged axillary lymph nodes ranging between 0.5-3cm.
- Sizable adjacent lesion. likely LN with multiple internal septations, peripheral nodularity and cystic changes, being similar to largest previously described left breast lesion.

(D) Axial T1WI is showing: These axillary lymph nodes are also extending to subpectoral and supraclavicular regions.

(E) Axial T2WI is showing: Infiltrative soft tissue heterogeneous lesion seen surrounding the left parasternal ribs and chest wall muscles with extension into mediastinal fat anterior to the heart.

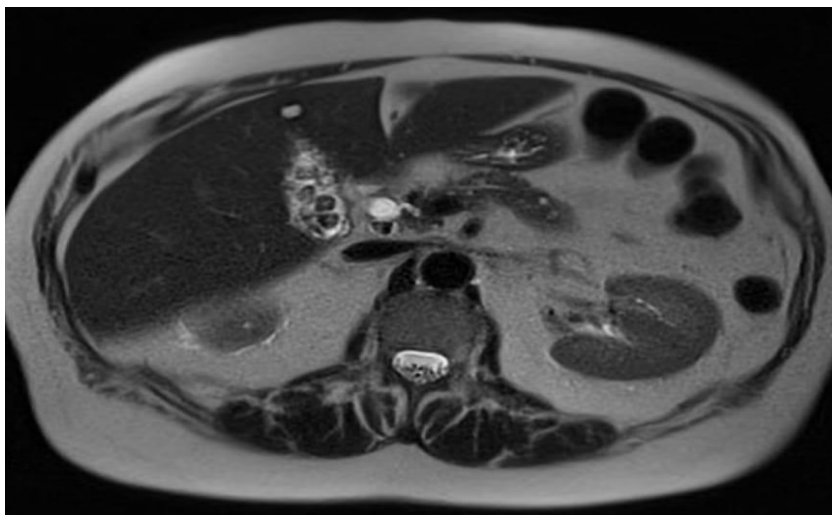


Figure 6. MRI breast study of 40 years old female patient with left breast highly suspicious of multifocal breast malignancy with worrisome apical group lymph nodes. (BI-RADS4c) with axial T2WI sequence showed calculi gall bladder.

Discussion

Few studies are reported in literature concerning the prevalence and the nature of extra-mammary findings on breast MRI. Rausch was the first describing few cases of extra-mammary findings on breast MRI (4). Afterwards, Morakabbati-Spitz et al., 2003 analyzed the prevalence and the type of extra-mammary findings in 1013 patients who underwent breast MRI as follow-up after breast cancer therapy, pre-operative staging, screening of high-risk patients or unclear clinical and mammographic examinations (6). The current study revealed the importance of extending the FOV in breast cancer patients who underwent breast MRI study.

As previously reported by Dietzel et al., 2012 that breast MR bases on the use of a dedicated surface breast coil that can scan a specific body region (7). Despite the presence of its technical and spatial limitations, anatomical structures included in the field of view (FOV) have to be considered. The evaluation of the mammary gland,

pectoralis muscles, skin, and axillary lymph nodes has to be completed by the observation of lungs, mediastinum, chest wall, spine, and upper abdominal organs. The pathological findings involving the chest and upper abdomen may be related or not to the breast disease, that was in agreement with the current study results that showed extending the FOV increase the incidence of EMF detection.

As the number of breast MR examinations increases, so does the number of incidental extramammary findings detected during the same examination. Some of these findings can often be clinically significant and would potentially alter patient management, requiring further investigations (4). The current study showed that among the described incidental findings was the pulmonary nodules whether metastatic or nonspecific. The same regarding the pleural pathologies as seen in the current study e.g. pleural effusion.

In this study the incidental extra-mammary findings were encountered in 69 (69%) of the 100 examined

patients. Our data resulted consistent with previous studies such as Rinaldi et al., 2011 (8) who retrospectively reviewed the data set of 1535 patients and reported extra-mammary findings in 18% of cases. Incidental findings were located in the liver in 51.9% and in lung, bone, mediastinal lymph nodes in smaller percentages. 20.4% of incidental findings were confirmed to be malignant. Nevertheless, malignant lesions were more frequently located within the bone, lymph nodes and lung than within the liver. In the current study 10/100 incidental findings (10%) were confirmed to be malignant while the remaining 90/100 (90%) benign. The most common site was the liver. Also among the most common incidental findings are the bony findings whether benign or malignant e.g. rib invasion whilst the benign findings are the most noticed in the current study as well as spine and vertebral findings: spondylo-degenerative changes and hemangiomas.

These results about hepatic incidental findings were subsequently matched with Iodice et al., 2013 (10) who retrospectively reviewed the data sets of 828 consecutive patients reporting collateral findings in 34% of patients with a prevalence of extra-mammary findings in examinations obtained for assessing lesion extent in patients with known breast tumor (52%). They showed that the probability of a hepatic lesion being malignant is less than 20%, even in patients with known primary breast cancer.

Among the important EMF is assessment of the supraclavicular lymph nodes extension that should be carefully evaluated in every case of MRI breast study. In this study we found cases of local extension that reaches the supraclavicular lymph nodes as well as the heart and mediastinum. These current study results were closely related to Yang et al. 2016 (11) who retrospectively reviewed the data set of 109 patients was found to have 149 incidental extramammary findings. His study incidental finding was found in the bone (43/149, 28.9%), liver (33/149, 22.1%), lung (32/149, 21.5%), pleura or chest wall (15/149, 10.1%), mediastinum (10/149, 6.7%), supraclavicular LN (9/149, 6.0%), and other sites (6/149, 4.7%). While in the current study, the most common site was the liver (38/69; 55.07%), followed by the bone (30/69; 43.47%).

Besides, although the relative small number of patients considered in the current study series, the potential role of extending the field of view in breast MRI in characterizing these incidental findings has been assessed as an additional element in this field. It is allowed to correctly characterize the extra-mammary lesions with a diagnostic accuracy value.

The current results are keeping with the results done by M. Moschetta et al. 2014 (9) that reported that breast

MRI represents a useful tool to detect and characterize extra-mammary lesions, although further imaging techniques were often necessary to precisely define incidental findings. In particular, CT and PET-CT were used to characterize lung lesions and dedicated MRI or bone scintigraphy to characterize bone lesions. Most of the remaining extra-mammary lesions detected on breast MRI, -such as hepatic, splenic ones, were evaluated by ultrasound. (9)

In our study group, the patient category who are newly diagnosed with breast cancer haven't yet developed a lot of extramammary findings so further wider scale of cases of patient studies in different phases of management either newly diagnosed or follow up after intervention as neo-adjuvant CTH, surgery or suspected recurrence are needed to be evaluated as it is expected to have more incidental EMF if we extend the FOV and this will affect the patient management and reinforce the importance of detecting the EMF in earlier studies. Relatively small sample size since this study is prospective study and the presence of some contraindication in some patients.

Conclusion and Recommendations

Breast MRI study should not be limited to the assessment of the mammary gland and the nodal involvement but should evaluate the extra-mammary structures where incidental findings whether benign or malignant with clinical relevance could be located. So extending the field of view is highly recommended as a routine protocol during the breast MRI study to increase the rate of detection of incidental extramammary findings to allow proper assessment, further follow and the treatment plan.

List of abbreviation:

ADC: apparent diffusion coefficient; DWI: diffusion-weighted imaging;
FOV: field of view;
LN(s): lymph node(s);
SI: signal intensity;
T1WI: T1-weighted imaging;
T2WI: T2-weighted imaging.
STIR: Short tau inversion recovery.

Conflicts of interest statement:

All authors have no conflicts of interest nor financial or personal relationships regarding this paper.

References:

1. Clauser P, Mann R, Athanasiou A, et al (2018). A survey by the European Society of Breast Imaging on the

- utilisation of breast MRI in clinical practice. *Eur Radiol.* 1909-1918.
2. Fancellu A, Soro D, Castiglia P, et al (2014). Usefulness of magnetic resonance in patients with invasive cancer eligible for breast conservation: a comparative study. *Clin Breast Cancer*; 14:114–21.
 3. Marinovich ML, Houssami N, Macaskill P, et al (2013). Meta-analysis of magnetic resonance imaging in detecting residual breast cancer after neoadjuvant therapy. *J Natl Cancer Inst*; 105:321–33.
 4. Rausch R (2008). Spectrum of extra-mammary findings on breast MRI: a pictorial review. *Breast J*; 14:591–600.
 5. Niell BL, Bennett D, Sharma A, et al (2015). Extramammary findings on breast MR examinations: frequency, clinical relevance, and patient outcomes. *Radiology*; 276:56–64.
 6. Morakkabati-Spitz N, Sondermann E, Schmiedel A, et al. Prevalence and type of incidental extra-mammary findings in MRI of the breast. *Rofo*2003; 175:199–202.
 7. Dietzel M, Zoubi R, Burmeister HP, et al (2012). Combined staging at one-stop using MR mammography: evaluation of an extended protocol to screen for distant metastasis in primary breast cancer—initial results and diagnostic accuracy in a prospective study. *Rofo*; 184:618–23.
 8. Rinaldi P, Costantini M, Belli P, et al (2011). Extramammary findings in breast MRI. *Eur Radiol.*; 21:2268–76.
 9. M. Moschetta et al. Prevalence of extra-mammary findings and their characterization on breast MRI. *European Journal of Radiology* 83 (2014) 930–934
 10. Iodice D, Di Donato O, Liccardo I, et al. Prevalence of extramammary findings on breast MRI: a large retrospective single-centre study. *Radiol Med* 2013, <http://dx.doi.org/10.1007/s11547-013-0937-8>.
 11. Yang et al. Extramammary findings on breast MRI: prevalence and imaging characteristics favoring malignancy detection: a retrospective analysis. *World Journal of Surgical Oncology* (2016) 14:119